

<ul style="list-style-type: none"><li>• Electronic copy is controlled under document control procedure. Hard copy is uncontrolled &amp; under responsibility of beholder.</li><li>• It is allowed ONLY to access and keep this document with who issued, who is responsible and to whom it is applicable.</li><li>• Information security code: <input checked="" type="checkbox"/> Open <input type="checkbox"/> Shared -Confidential <input type="checkbox"/> Shared-Sensitive <input type="checkbox"/> Shared-Secret</li></ul>	<ul style="list-style-type: none"><li>• النسخة الإلكترونية هي النسخة المضبوطة وفق إجراء ضبط الوثائق- النسخ الورقية غير مضبوطة وتقع على مسؤولية حاملها.</li><li>• يسمح بالوصول وباحتفاظ بهذه الوثيقة مع مصدرها أو مع المسؤول عن تطبيقها أو مع المطبق عليهم.</li><li>• تصنيف امن المعلومات: <input checked="" type="checkbox"/> بيانات مفتوحة <input type="checkbox"/> مشارك -خاص <input type="checkbox"/> مشارك -حساس <input type="checkbox"/> مشارك -سري</li></ul>
--	--

# DHA TELEHEALTH CLINICAL GUIDELINES

## FOR VIRTUAL MANAGEMENT OF

### CONJUNCTIVITIS - 25

**Issue date:** 27/07/2021

**Effective date:** 27/07/2021

Health Policies and Standards Department  
Health Regulation Sector (2021)

## INTRODUCTION

Dubai Health Authority (DHA) is the responsible entity for regulating, licensing and monitoring health facilities and healthcare professionals in the Emirate of Dubai. The Health Regulation Sector (HRS) is an integral part of DHA and was founded to fulfil the following overarching strategic objectives:

Objective #1: Regulate the Health Sector and assure appropriate controls are in place for safe, effective and high-quality care.

Objective #2: Position Dubai as a global medical destination by introducing a value-based, comprehensive, integrated and high-quality service delivery system.

Objective #3: Direct resources to ensure happy, healthy and safe environment for Dubai population.

## ACKNOWLEDGMENT

This document was developed for the Virtual Management of Neck Pain in collaboration with Subject Matter Experts. The Health Policy and Standards Department would like to acknowledge and thank these professionals for their dedication toward improving the quality and safety of healthcare services.

### The Health Regulation Sector

### Dubai Health Authority

## TABLE OF CONTENTS

<b>EXECUTIVE SUMMARY</b>	<b>4</b>
<b>DEFINITIONS/ABBREVIATIONS</b>	<b>5</b>
<b>1. BACKGROUND</b>	<b>6</b>
<b>2. SCOPE</b>	<b>6</b>
<b>3. PURPOSE</b>	<b>6</b>
<b>4. APPLICABILITY</b>	<b>6</b>
<b>5. ETIOLOGY</b>	<b>6</b>
<b>6. RED FLAGS</b>	<b>13</b>
<b>7. DIAGNOSIS</b>	<b>15</b>
<b>8. MANAGEMENT</b>	<b>18</b>
<b>9. REFERRAL CRITERIA</b>	<b>21</b>
<b>REFERENCES</b>	<b>24</b>
<b>APPENDICES</b>	<b>25</b>

## EXECUTIVE SUMMARY

Telehealth is based on Evidence Based Practice (EBP) which is the conscientious, explicit and judicious use of current best evidence in making decisions about the care of the individual patient.

It means integrating individual clinical expertise with the best available external clinical evidence and guidelines from systematic research.

EBP is important because it aims to provide the most effective care virtually, with the aim of improving patient outcomes. As health professionals, part of providing a professional service is ensuring that practice is informed by the best available evidence.

Conjunctivitis is a common patient complaint. It is the most likely diagnosis in a patient with a red eye and discharge.

Acute conjunctivitis is usually a benign, self-limited condition or one that is easily treated. When making a diagnosis of acute conjunctivitis, one needs to make certain that sight-threatening and pathologic processes have been ruled out.

This clinical guideline for the virtual management of Conjunctivitis is presented in the format comprising of clinical history/symptoms, differential diagnosis, investigations and management. Identification of 'Red Flags' or serious conditions associated with the disease is an essential part of this telehealth guideline as it aids the physician to manage patients safely and appropriately by referrals, if indicated during virtual telehealth assessment, to ER, family physicians or specialists for a face to face management.

## DEFINITIONS/ABBREVIATIONS

**Virtual Clinical Assessment:** Is the evaluation of the patient's medical condition virtually via telephone or video call consultations, which may include one or more of the following: patient medical history, physical examination and diagnostic investigations.

**Patient:** The person who receives the healthcare services or the medical investigation or treatment provided by a DHA licensed healthcare professional.

## ABBREVIATIONS

<b>DFA</b>	:	Direct Fluorescent Antibody
<b>DHA</b>	:	Dubai Health Authority
<b>EBP</b>	:	Evidence Based Practice
<b>EKC</b>	:	Epidemic Keratoconjunctivitis
<b>ER</b>	:	Emergency Room
<b>HRS</b>	:	Health Regulation Sector
<b>IgE</b>	:	Immunoglobulin E
<b>OTC</b>	:	Over the Counter
<b>PCR</b>	:	Polymerase Chain Reaction

## 1. BACKGROUND

1.1. Conjunctivitis literally means "inflammation of the conjunctiva." The conjunctiva is the mucous membrane that lines the inside surface of the lids and covers the surface of the globe up to the limbus (the junction of the sclera and the cornea).

1.2. All conjunctivitis is characterized by a red eye, but not all red eyes are conjunctivitis.

## 2. SCOPE

2.1. Telehealth services in DHA licensed Health Facilities.

## 3. PURPOSE

3.1. To support the implementation of Telehealth services for patients with complaints of Conjunctivitis in Dubai Health Authority (DHA) licensed Health Facilities

## 4. APPLICABILITY

4.1. DHA licensed physicians and health facilities providing Telehealth services.

4.2. Exclusion for Telehealth services are as follows

4.2.1. Emergency cases where immediate intervention or referral is required.

4.2.2. Prescribe Narcotics, Controlled or Semi-Controlled medications.

## 5. ETIOLOGY

5.1. Acute conjunctivitis can be classified as infectious or non-infectious and further divided into four main types:

5.1.1. Infectious

a. Bacterial (in children more than adult).

b. Viral (more common, in both adult and children).

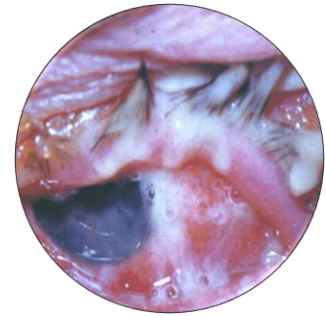5.1.2. Non-infectious

a. Allergic

b. Nonallergic

5.2. Bacterial conjunctivitis

5.2.1. Bacterial conjunctivitis is commonly caused by *Staphylococcus aureus*, *Streptococcus pneumoniae*, *Haemophilus influenzae*, and *Moraxella catarrhalis*. *S. aureus* infection



is common in adults; the other pathogens are more common in children.

5.2.2. Bacterial conjunctivitis is spread by direct contact with the patient and his or her secretions or with contaminated objects and surfaces. It is highly contagious.

5.2.3. Patients with bacterial conjunctivitis typically complain of redness and discharge in one eye, although it can also be bilateral. Similar to viral and allergic conjunctivitis, the affected eye often is "stuck shut" in the morning.

5.2.4. Clinically - the discharge is thick and globular; it may be yellow, white, or green. The appearance differs from that of viral or allergic conjunctivitis,

which often present with a mostly watery discharge during the day, with a scanty, stringy component that is mucus rather than pus.

### 5.3. Hyperacute bacterial conjunctivitis

- 5.3.1. Causes; *Neisseria* species, particularly *N. gonorrhoeae*, can cause a hyperacute bacterial conjunctivitis that is severe and sight-threatening, requiring immediate ophthalmologic referral. The organism is usually transmitted from the genitalia to the hands and then to the eyes. Concurrent urethritis is typically present.
- 5.3.2. The eye infection is characterized by a profuse purulent discharge present within 12 hours of inoculation, the amount of discharge is striking.
- 5.3.3. Other symptoms are rapidly progressive and include redness, irritation, and tenderness to palpation. There is typically marked chemosis, lid swelling, and tender preauricular adenopathy.
- 5.3.4. Gram-negative diplococci can be identified on Gram stain of the discharge.
- 5.3.5. These patients require hospitalization for systemic and topical therapy and for monitoring of the ocular component. Keratitis and perforation can occur.



#### 5.4. Trachoma

5.4.1. It is a Chlamydial infection

5.4.2. Conjunctivitis is the major clinical manifestation of active trachoma, a disorder that is largely limited to endemic areas in underdeveloped regions.

#### 5.5. Adult inclusion conjunctivitis

5.5.1. Adult inclusion conjunctivitis is not strictly an acute conjunctivitis but rather a chronic, indolent conjunctivitis.

5.5.2. It is a sexually transmitted infection caused by certain serotypes of *Chlamydia trachomatis*.

5.5.3. Concurrent asymptomatic urogenital infection is typically present.

5.5.4. The eye infection presents as a unilateral, or sometimes bilateral, follicular conjunctivitis of weeks to months duration that has not responded to topical antibiotic therapy. There can be an associated keratitis.

5.5.5. Diagnosis is confirmed with Giemsa or direct fluorescent antibody (DFA) staining of conjunctival smears or by culture or polymerase chain reaction (PCR) of swabbed specimens.

## 5.6. Viral conjunctivitis

5.6.1. Is typically caused by adenovirus, with many serotypes implicated

5.6.2. Highly contagious; it is spread by direct contact with the patient and his or her

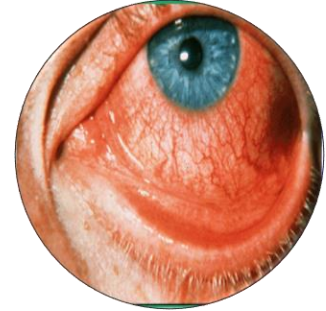
secretions or with contaminated objects and surfaces

5.6.3. May be part of a viral prodrome followed by adenopathy, fever, pharyngitis, and upper respiratory tract infection, or the eye infection may be the only manifestation of the disease.

5.6.4. Typically presents as injection, watery or mucoserous discharge and a burning, sandy, or gritty feeling in one eye. Patients may report "pus" in the eye, as morning crusting followed by watery discharge, perhaps with some scanty mucus throughout the day.

5.6.5. The second eye usually becomes involved within 24 to 48 hours, although unilateral signs and symptoms do not rule out a viral process

5.6.6. It is a self-limited process. While recovery can begin with days, the symptoms frequently get worse for the first three to five days, with very gradual resolution over the following one to two weeks for a total course of two to three weeks.



5.6.7. Patients with viral conjunctivitis may have morning crusting two weeks after the initial symptoms, although the daytime redness, irritation, and tearing should be much improved.

5.7. Epidemic keratoconjunctivitis

5.7.1. One form of viral conjunctivitis, epidemic keratoconjunctivitis (EKC), is particularly fulminant, causing a keratitis (inflammation of the cornea) in addition to conjunctivitis.

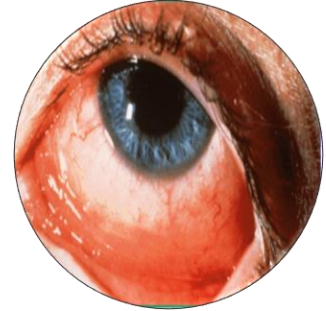
5.7.2. It is typically caused by adenovirus types 8, 19, and 37, the same viral strain that causes EKC in one patient may cause ordinary viral conjunctivitis in another, probably due to variation in host immune factors.

5.7.3. In addition to the typical symptoms of viral conjunctivitis, the patient develops a foreign body sensation and multiple corneal infiltrates. The foreign body sensation is severe enough to preclude opening the eyes spontaneously, and the infiltrates typically degrade acuity by two or three lines to the 20/40 range.

5.7.4. Keratitis is potentially vision-threatening, and these patients should be referred to an ophthalmologist to confirm the diagnosis and to decide if a course of topical glucocorticoids is warranted.

## 5.8. Allergic conjunctivitis

5.8.1. Allergic conjunctivitis is caused by airborne allergens contacting the eye that, with specific immunoglobulin E (IgE).



5.8.2. Presents as bilateral redness, watery discharge, and itching. Itching is the cardinal symptom of allergy, distinguishing it from a viral etiology, which is more typically described as grittiness, burning, or irritation. Eye rubbing can worsen symptoms.

5.8.3. Patients with allergic conjunctivitis often have a history of atopy, seasonal allergy, or specific allergy (e.g., to cats). There may be morning crusting. It is the complaint of itching and the history of allergy or hay fever as well as a recent exposure that allows the distinction between allergic and viral conjunctivitis; the clinical findings are the same.

5.8.4. In some cases of allergic conjunctivitis, there is marked chemosis (conjunctival edema); in extreme instances, there can be bullous chemosis, in which the bulging, edematous conjunctiva extends forward beyond the lid margins.

5.9. Non-infectious, nonallergic conjunctivitis

- 5.9.1. Patients can develop a red eye and discharge that is not related to an infectious or inflammatory process. Usually the cause is a transient mechanical or chemical insult.
- 5.9.2. The discharge is more likely mucus than pus.
- 5.9.3. Patients with dry eye may report chronic or intermittent redness or discharge and may interpret these symptoms as being related to an infectious cause.
- 5.9.4. Patients whose eyes are irrigated after a chemical splash may have redness and discharge; this is often related to the mechanical irritation of irrigation rather than superinfection.
- 5.9.5. A patient with an ocular foreign body that was spontaneously expelled may have redness and discharge for 12 to 24 hours.
- 5.9.6. All these causes generally improve spontaneously within 24 hours.

**6. RED FLAGS**

- 6.1. Warning signs of more serious problems that should prompt evaluation by an ophthalmologist include: Reduction of visual acuity (concerns about infectious keratitis, iritis, angle-closure glaucoma)

- 6.1.1. Ciliary flush – A pattern of injection in which the redness is most pronounced in a ring at the limbus, (the transition zone between the cornea and the sclera). This is concerning for infectious keratitis, iritis, and angle-closure glaucoma.
- 6.1.2. Photophobia (concerns about infectious keratitis, iritis).
- 6.1.3. Severe foreign body sensation that prevents the patient from keeping the eye open (concerns about infectious keratitis)
- 6.1.4. Corneal opacity (concerns about infectious keratitis).
- 6.1.5. Fixed pupil (concerns about angle-closure glaucoma).
- 6.1.6. Severe headache with nausea (concerns about angle-closure glaucoma)
- 6.1.7. Post traumatic red eye
- 6.1.8. Immuno-compromised patient
- 6.2. Refer to APPENDIX 1 for the Assessment of the Red Eye Table
- 6.3. Red eyes that may be managed by the telehealth primary care clinician
  - 6.3.1. Sty (hordeoleum)
  - 6.3.2. Chalazion
  - 6.3.3. Blepharitis
  - 6.3.4. Subconjunctival hemorrhage
  - 6.3.5. Conjunctivitis
  - 6.3.6. Bacterial

- 6.3.7. Viral
- 6.3.8. Allergic
- 6.3.9. Dry eye syndrome
- 6.3.10. Episcleritis

## 7. DIAGNOSIS

### 7.1. General approach and differential diagnosis

Conjunctivitis is a clinical diagnosis of exclusion. Consultation should be done via video. The diagnosis can be made in a patient with a red eye and discharge only if:

- 7.1.1. the vision is normal and
- 7.1.2. there is no suggestive history of keratitis, iritis, or angle-closure glaucoma.

### 7.2. History

Patients with all types of conjunctivitis complain of morning crusting and daytime redness and discharge.

### 7.3. Questions of significance:

- 7.3.1. Is vision affected? (May requires a clinician examination and referral to specialist)
- 7.3.2. Is there a foreign body sensation?
  - a. If Objective sensation (evidence of foreign body sensation, in which the patient is unable to spontaneously open the eye or keep it open),

then needs Emergency Department or Urgent Ophthalmologist referral.

- b. Whereas Subjective foreign body sensation, as "scratchy feeling," "grittiness," or a sensation "like sand in my eyes" is noted with allergy, viral conjunctivitis, or dry eyes.

7.3.3. Is there photophobia? – If yes, will need a face to face consultation.

- a. Patients with active corneal process have objective signs of photophobia (avoiding light), with objective signs of foreign body sensation.
- b. Patients with iritis have objective signs of photophobia but no objective foreign body sensation.

7.3.4. Was there trauma?

7.3.5. Are you a contact lens wearer? (suspicion for keratitis).

7.3.6. Is there discharge, other than tears, that continues throughout the day? Patients typically interpret morning crusting as "pus."

7.4. Pitfalls in diagnosis

7.4.1. Patients often call all cases of red eye "conjunctivitis" and presume that all cases are bacterial and require antibiotics. When a patient call to report "conjunctivitis" or "pink eye," physicians should not accept that as



a diagnosis but should rather review the history, symptoms, and signs prior to treating.

7.4.2. One should be wary of the diagnosis of conjunctivitis in any patient with a recent history of trauma; there may be a corneal or conjunctival foreign body or traumatic iritis. Warning signs for sight-threatening conditions should be excluded.

7.4.3. Patients will call all types of discharge "pus." It is worthwhile to distinguish the character of the discharge to make a more specific diagnosis. As mentioned above, in bacterial conjunctivitis the complaint of discharge predominates, while in viral and allergic conjunctivitis patients report a burning and gritty feeling or itching.

#### 7.5. Contact lens wearers

7.5.1. The diagnosis of conjunctivitis should be made carefully in contact lens wearers, who are subject to multiple secondary chronic conjunctivitis that require a change in contact lens fit, lens type, or lens hygiene and may require suppression of hypersensitivity.

7.5.2. More importantly, soft contact lens wearers have a high risk of pseudomonal keratitis, especially with use of extended-wear lenses. This causes an acute red eye and discharge in association with an ulcerative keratitis. The ulcerative keratitis can lead to ocular perforation within 24

hours if it is not recognized and treated appropriately. Thus, the presence of keratitis should be ruled out prior to presuming and treating conjunctivitis. Keratitis causes objective foreign body sensation, and the patient is usually unable to spontaneously open the eye or keep it open.

- 7.5.3. A contact lens wearer with an acute red eye and discharge should be advised to discontinue contact lens wear immediately and to be seen by an ophthalmologist if the symptoms do not improve in 12 to 24 hours.

## 8. MANAGEMENT

- 8.1. Refer to APPENDIX 1 for the Virtual Management of Conjunctivitis Algorithm

- 8.2. General considerations

Viral, allergic, and nonspecific conjunctivitis are all self-limited processes; specific therapy reduces symptoms but does not alter the clinical course. Bacterial conjunctivitis is also self-limited in most cases, but topical antibiotic eye drops may shorten the clinical course if given before day 6.

- 8.3. Empiric therapy

In principle, only those diagnosed with bacterial conjunctivitis should receive antibiotics.

- 8.4. Specific therapy: Bacterial

- 8.4.1. Refer to APPENDIX 2 for Antibiotic Therapy Summary

- 8.4.2. Patients should respond to treatment within one to two days by showing a decrease in discharge, redness, and irritation.
- 8.4.3. Patients who do not respond should be referred to an ophthalmologist.
- 8.4.4. Antibiotics choice may depend on certain considerations:
- a. Children  
Ointment is preferred over drops for children or those with poor compliance.
  - b. Contact lens wearers  
Fluoroquinolones are not first-line therapy for routine cases of bacterial conjunctivitis because of concerns regarding emerging resistance and cost.  
The exception is conjunctivitis in a contact lens wearer once keratitis has been ruled out, it is reasonable to treat these individuals with a fluoroquinolone due to the high incidence of *Pseudomonas* infection.  
The fluoroquinolones are effective, well-tolerated, and extremely effective against *Pseudomonas*.  
Any contact lens wearer with a red eye should discontinue contact lens wear. If the diagnosis is conjunctivitis, contact lens wear can resume when the eye is white and has no discharge for 24 hours after the completion of antibiotic therapy. The lens case should be

discarded and the lenses subjected to overnight disinfection or replaced if disposable.

8.5. Specific Therapy: Viral

8.5.1. There is no specific antiviral agent for the treatment of viral conjunctivitis.

8.5.2. Symptomatic relief from topical antihistamine/decongestants. These are available over-the-counter (Naphazoline Hydrochloride, Pheniramine Maleate)

8.5.3. Patients must be told that the eye irritation and discharge may get worse for three to five days before getting better, that symptoms can persist for two to three weeks, and that use of any topical agent for that duration might result in irritation and toxicity, which can itself cause redness and discharge.

8.5.4. Patient education is often more effective than prolonged or additional therapies.

8.6. Adult inclusion conjunctivitis

8.6.1. Systemic therapy is required to eradicate the *C. trachomatis* infection. Treatment is typically with doxycycline, tetracycline, erythromycin, or azithromycin.

8.7. Allergic

8.7.1. Antihistamine/decongestants drops.

8.8. Non-infectious nonallergic

8.8.1. The conjunctival surface regenerates rapidly from insults that precipitate noninfectious conjunctivitis, leading to spontaneous resolution of symptoms.

8.8.2. OTC Lubricants will help. Lubricant drops can be used as often as hourly with no side effects. Preferably at bedtime.

8.8.3. It may be worthwhile to switch brands if a patient finds one brand of drop or ointment irritating since each preparation contains different active ingredients, vehicles, and preservatives.

**9. REFERRAL CRITERIA**

9.1. Referral to Family Physician/ Specialist Ophthalmologist

9.1.1. Persistent symptoms

9.1.2. Delayed response of more than 5 to 7 days

9.1.3. Reduction of visual acuity

9.1.4. Ciliary flush

9.1.5. Corneal opacity

9.1.6. Photophobia

9.1.7. Immune-compromised patient

9.2. Referral to Emergency Department

9.2.1. Fixed pupil/ painful red eye

9.2.2. Red eye with severe headache with nausea

9.2.3. Hyphema

9.2.4. Hypopyon

9.2.5. Post traumatic red eye

9.2.6. Severe foreign body sensation that prevents the patient from keeping the eye open

9.3. Work/school

9.3.1. It is recommended to advise patients those who have contact with the very old, the very young, and immune-compromised individuals should take care to avoid spread of infection from their eye secretions to these susceptible people.

9.4. Sports

9.4.1. For bacterial conjunctivitis, patients should not return to playing sports until they have used an antibiotic for a minimum of 24 hours and had resolution of eye drainage. Clearance to return to play depends on the sport.

9.4.2. Athletes who participate in sports that are individual and/or noncontact sports (e.g., cross-country running) can return when they feel able and

can see clearly. If these athletes return before symptoms have resolved, they should be advised not to touch their eyes and to wash their hands frequently.

- 9.4.3. Athletes who participate in contact sports or water-based sports may return to play once daytime discharge has abated, typically after about five days.

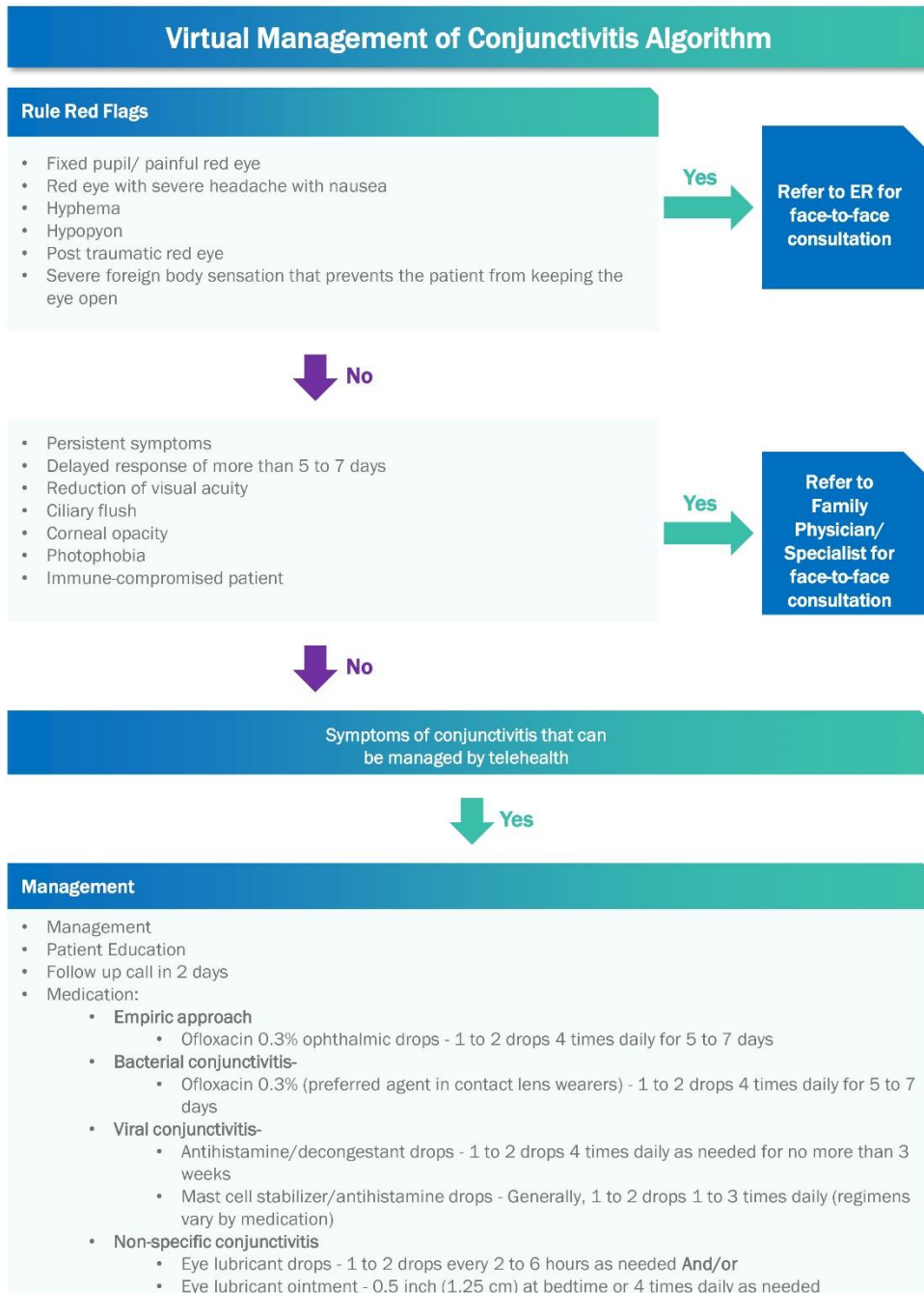
## REFERENCES

1. Jacobs, D. (2019). *Conjunctivitis*. [online] Uptodate.com. Available at: [https://www.uptodate.com/contents/conjunctivitis?search=conjunctivitis&source=search\\_result&selectedTitle=1~150&usage\\_type=default&display\\_rank=1](https://www.uptodate.com/contents/conjunctivitis?search=conjunctivitis&source=search_result&selectedTitle=1~150&usage_type=default&display_rank=1) [Accessed 17 Jul. 2019].
2. Knott, L. (2007). *The treatment of conjunctivitis*. [online] Gponline.com. Available at: <https://www.gponline.com/treatment-conjunctivitis/ophthalmology/article/649902> [Accessed 17 Jul. 2019].
3. Morrow, G.L. and Abbott, R.L. (2013). Conjunctivitis. *American Family Physician*, [online] 57(4), p.735. Available at: <https://www.aafp.org/afp/1998/0215/p735.html> [Accessed 17 Jul. 2019].



## APPENDICES

### APPENDIX 1 – VIRTUAL MANAGEMENT OF CONJUNCTIVITIS ALGORITHM



## APPENDIX 2 – ANTIBIOTIC THERAPY SUMMARY

Therapy of conjunctivitis	Dose
<b>Empiric approach</b>	
Ofloxacin 0.3% ophthalmic drops (preferred agent in contact lens wearer) OR	1 to 2 drops 4 times daily for 5 to 7 days
Ciprofloxacin 0.3% ophthalmic drops (preferred agent in contact lens wearer) OR	1 to 2 drops 4 times daily for 5 to 7 days
<b>Specific approach</b>	
<b>Bacterial conjunctivitis</b>	
Ofloxacin 0.3% (preferred agent in contact lens wearers) OR	1 to 2 drops 4 times daily for 5 to 7 days
Ciprofloxacin 0.3% ophthalmic drops (preferred agent in contact lens wearer) OR	1 to 2 drops 4 times daily for 5 to 7 days
Azithromycin 1% ophthalmic drops	1 drop twice a day for 2 days; then 1 drop daily for 5 days
<b>Viral conjunctivitis</b>	
Antihistamine/decongestant drops (OTC)	1 to 2 drops 4 times daily as needed for no > 3 weeks
<b>Allergic conjunctivitis</b>	
Antihistamine/decongestant drops (OTC)	1 to 2 drops 4 times daily as needed for no > 4 weeks
Mast cell stabilizer/antihistamine drops	1 to 2 drops 1 to 3 times daily (regimens vary by drug)
<b>Non-specific conjunctivitis</b>	
Eye lubricant drops (OTC) <b>AND/OR</b>	1 to 2 drops every 2 to 6 hours as needed
Eye lubricant ointment (OTC)	0.5 inch (1.25 cm) at bedtime or 4 times daily as needed